



**PATIENT**

Chloe Buckles

**SPECIES**

Canine

**BREED**

Lhasa Apso

**SEX**

Female Spayed

**AGE**

11 years

**WEIGHT**

14lbs

**INTERPRETED BY**

Maggie Machen Lamy,  
DVM, DACVIM  
(Cardiology)

**IMAGING PERFORMED BY**

Kelly Vazquez, CVT

**HOSPITAL NAME**

Ho Ho Kus Veterinary  
Hospital

**REFERRING VET**

Dr. Gannon

**INVOICE**

31816

**DATE**

7/12/23

**PRESENTING CLINICAL SIGNS**

History: Grade 2/6 heart murmur. Assess prior to anesthesia. Sometimes she will cough but "nothing comes up" per the owner.

-Current medications: Vetmedin 1.5mgs 1.5 BID, Norvasc 2.5mgs 1/2 SID.

-Abnormal PE/Chem/CBC/UA Results: CBC/Chem/T4: WNL.

**ECHOCARDIOGRAM FINDINGS**

2D, m-mode, color flow and doppler imaging is available. Mild diffuse thickening of mitral valve leaflets with no prolapse into the left atrial lumen. Mild eccentric mitral regurgitation with no left atrial dilation. Normal LV diameter with adequate myocardial function. The tricuspid valve appears normal with mild tricuspid regurgitation. Normal right atrial and ventricular diameter and morphology indicating no overt evidence of pulmonary arterial hypertension. The pulmonic and aortic valves are normal in morphology and mobility. Normal pulmonic and aortic outflow velocities with laminar flow. No obvious aortic or pulmonic insufficiency. No pericardial or pleural effusion noted. No obvious cardiac masses.

**CARDIAC CHART**

CANINE CARDIAC PARAMETERS	MR VMAX (m/s)	TR VMAX (m/s)	LA/AO (Boon method)	LA/AO (Heart Base; Swe)	FS (%)	EF (%)	EPSS (cm)
NORMAL PARAMETER	4.5-5.5	<2.7	1.3	<1.6	28-40	40-100	<0.6
PATIENT	NM	NM	NM	1.2	30	60	NM
CANINE CARDIAC PARAMETERS	HR (BPM)	AV VMAX (m/s)	PV MAX (m/s)	BODY WEIGHT (kg)	LA 2D short axis Base view (cm)	LVIDd Avg: 2D and m-mode short axis (cm)	LVIDs Avg: 2D and m-mode short axis (cm)
NORMAL PARAMETER	50-100	0.7-1.7	0.7-1.6	BELOW	BELOW	BELOW	BELOW
PATIENT	120	1.1	1.0	6.4	1.5	2.4	1.7
*Normal chamber parameters expressed as a mean value (SD)				3	1.27 (5.3)	2.46 (2.46)	1.36 (5.5)
<b>BODY WEIGHT DEPENDENT PARAMETERS</b>				5	1.40 (4.5)	2.74 (5.2)	1.60 (4.7)
<i>*Note: All measurements based upon multi-modal images and methods. An average value is reported.</i>				10	1.50 (3.8)	3.27 (3.5)	2.06 (3.1)
				15	1.83 (2.0)	3.71 (2.4)	2.43 (2.1)
				20	2.02 (1.9)	4.14 (2.2)	2.80 (2.0)
				25	2.18 (2.4)	4.48 (2.9)	3.10 (2.5)
				30	2.33 (3.3)	4.83 (3.9)	3.39 (3.4)
				35	2.48 (4.3)	5.17 (5.0)	3.69 (4.5)
				40	2.62 (5.2)	5.48 (6.1)	3.96 (5.4)
				50	2.88 (7.1)	6.07 (8.3)	4.46 (7.4)

**INTERPRETATION OF THE FINDINGS & FURTHER RECOMMENDATIONS**

Chronic degenerative valve disease causing mild mitral and tricuspid regurgitation. Lack of significant left atrial enlargement indicates the current risk for complication is low. No concurrent issues such as systolic dysfunction or pulmonary hypertension are noted in this study.

Given these findings, the cough is unlikely to be cardiac in origin and primary respiratory causes should be considered. Consider further respiratory work up/treatment (hydrocodone, taper course of steroids, Enrofloxacin, TTW/BAL, etc).



## PATIENT

Chloe Buckles

## SPECIES

Canine

## BREED

Lhasa Apso

## SEX

Female Spayed

## AGE

11 years

## WEIGHT

14lbs

## INTERPRETED BY

Maggie Machen Lamy,  
DVM, DACVIM  
(Cardiology)

## IMAGING PERFORMED BY

Kelly Vazquez, CVT

## HOSPITAL NAME

Ho Ho Kus Veterinary  
Hospital

## REFERRING VET

Dr. Gannon

## INVOICE

31816

## DATE

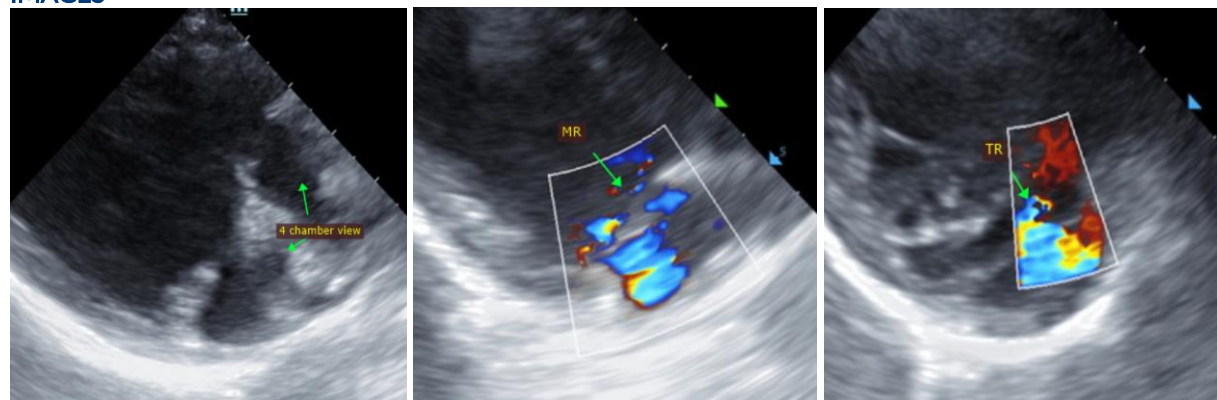
7/12/23

Given these findings, no cardiac medications are indicated and Pimobendan can be safely discontinued. No indication for Amlodipine in the absence of systemic hypertension. Assessment of progression in the future will help predict long term prognosis, which is highly variable at this stage (B1). Omega fatty acid supplementation and mild salt restriction may be of some long-term benefit. Monitor for development of a cough, labored breathing, exercise intolerance or collapse episodes.

Anesthetic risk is considered mild if needed. Cardiac protective drug choices (opioid/benzodiazepine premedication, propofol or alfaxalone induction, isoflurane gas) are recommended. Pre-oxygenate for 5-10 minutes prior to induction. Monitor for arrhythmias, hypotension, and hypoxia both intra and post-operatively and intervene as necessary. Mild IV fluid restriction is recommended to avoid fluid overload. Avoid heart rate stimulating drugs such as atropine unless clinically indicated.

Recommend conservative monitoring with a recheck echocardiogram in 6-12 months, sooner if any development of clinical signs.

## IMAGES



The information and recommendations provided are based on the images presented by the referring veterinarian. No evaluation can be communicated regarding pathology that was not visible in the image/video clips provided.

Thank you for this referral. This report was generated using transcription software, and minor dictation errors may be present. If the clinical or image interpretation does not parallel your findings or if I can be of any further assistance, please contact me.

Maggie Machen Lamy, DVM  
Diplomate of the American College of Veterinary Internal Medicine (Cardiology)  
info@sonopath.com



**PATIENT**

Chloe Buckles

**SPECIES**

Canine

**BREED**

Lhasa Apso

**SEX**

Female Spayed

**AGE**

11 years

**WEIGHT**

14lbs

**INTERPRETED BY**

Maggie Machen Lamy,  
DVM, DACVIM  
(Cardiology)

**IMAGING  
PERFORMED BY**

Kelly Vazquez, CVT

**HOSPITAL NAME**

Ho Ho Kus Veterinary  
Hospital

**REFERRING VET**

Dr. Gannon

**INVOICE**

31816

**DATE**

7/12/23